



Case report: tularaemia in a white-handed gibbon (*Hylobates lar*), Germany

Calvin Mehl, Kerstin Mätz-Rensing, Jörg Linde, Barbara Struve, Gabriele Ismer, Christiane van Hümmel, Rainer G. Ulrich & Herbert Tomaso

To cite this article: Calvin Mehl, Kerstin Mätz-Rensing, Jörg Linde, Barbara Struve, Gabriele Ismer, Christiane van Hümmel, Rainer G. Ulrich & Herbert Tomaso (2023) Case report: tularaemia in a white-handed gibbon (*Hylobates lar*), Germany, International Journal of Veterinary Science and Medicine, 11:1, 121-125, DOI: [10.1080/23144599.2023.2264084](https://doi.org/10.1080/23144599.2023.2264084)

To link to this article: <https://doi.org/10.1080/23144599.2023.2264084>



© 2023 The Author(s). Published by Informa UK Limited, trading as Taylor & Francis Group.



[View supplementary material](#)



Published online: 24 Oct 2023.



[Submit your article to this journal](#)



[View related articles](#)



[View Crossmark data](#)

Case report: tularaemia in a white-handed gibbon (*Hylobates lar*), Germany

Calvin Mehl ^{a,b}, Kerstin Mätz-Rensing^c, Jörg Linde ^d, Barbara Struve^e, Gabriele Ismer^f,
Christiane van Hümmel^g, Rainer G. Ulrich ^{a,b} and Herbert Tomaso ^d

^aFriedrich-Loeffler-Institut (FLI), Federal Research Institute for Animal Health, Institute of Novel and Emerging Infectious Diseases (INNT), Greifswald, Germany; ^bGerman Centre for Infection Research (DZIF), Partner Site Hamburg-Lübeck-Borstel- Riems, Greifswald, Germany; ^cGerman Primate Center GmbH (DPZ), Leibniz Institute for Primate Research, Göttingen, Germany; ^dFriedrich-Loeffler-Institut (FLI), Federal Research Institute for Animal Health, Institute for Bacterial Infections and Zoonoses (IBIZ), Jena, Germany; ^eLeintal Zoo, Schwaigern, Germany; ^fTierpark Gettorf GmbH, Gettorf, Germany; ^gVeterinary Practice Gettorf, Gettorf, Germany

ABSTRACT

In 2021, a white-handed gibbon (*Hylobates lar*) succumbed to illness shortly after transfer from one zoo to another in Germany, due to *Francisella tularensis* subsp. *holarctica* infection. To determine the source of infection, whole genome sequencing of the gibbon-derived isolate was performed and wild pest rodents (and captive squirrels) from both zoos were screened for *F. tularensis*. The *F. tularensis* whole genome sequence obtained from the gibbon was closely related to previous subclade B.281 sequences obtained from hares from Baden-Wuerttemberg, the same region where the gibbon was first housed. However, *F. tularensis* DNA was detected in one Norway rat from the receiving zoo. Therefore, neither zoo can be excluded as the source of infection.

ARTICLE HISTORY

Received 25 May 2023
Revised 4 September 2023
Accepted 5 September 2023

KEYWORDS

Francisella tularensis;
tularaemia; gibbon; rodents;
hylobates lar

1. Introduction





Tularaemia is a zoonotic disease caused by the Gram-negative, intracellular bacterium *Francisella tularensis* [1]. In Germany, most human or animal infections result from contact with European brown hares (*Lepus europaeus*) infected with *F. tularensis* subsp. *holarctica* [1]. However, infections may also occur through bites from infected arthropods; ingestion of contaminated food or water; contact with a contaminated hydrotelluric environment; or the inhalation of infectious aerosols [2]. Depending on the route of transmission, the infection may present differently [3]. Several vole species and yellow-necked field mice (*Apodemus flavicollis*) have also been shown to be potential carriers of the pathogen in Germany [4,5].

Tularaemia re-emerged in Germany in 2004 with infections of hare hunters in Hesse [6] and the death of five common marmosets (*Callithrix jacchus*) at a research facility reported in Lower Saxony [7]. Reports of human cases have been steadily increasing, with 435 cases reported between 2002 and 2019 – though the number of undiagnosed cases is believed to be substantially higher [8].

2. The study

In September 2021, a female white-handed gibbon (*Hylobates lar*, born April 2014) was transferred

from a zoo in the federal state Baden-Wuerttemberg to a zoo in Schleswig-Holstein and succumbed to illness ten days later. No other animals or caretakers from either zoo showed symptoms of infection. At the receiving zoo, the gibbon was housed with outdoor access, adjacent to an outdoor rabbit exhibit, during the day. Ultrasound showed fluid accumulation in the abdomen, predominantly around the liver and bladder (Figure 1). The gibbon presented with diarrhoea and general discomfort (rectal 38.7°C). Auscultation of the heart and lungs, and palpation of the abdomen found no abnormalities. Amoxicillin (105 mg, Duphamox® LA) and Metamizole (350 mg, Metapyrin®) were administered subcutaneously. The following day, the gibbon was found unresponsive, presenting with yellowish mucosa, and a weak and irregular heartbeat (rectal temperature 36.5°C). An abdominal ultrasound revealed hyperechogenic liver and free abdominal fluid caudal of the liver and around the bladder. X-rays showed this in slightly reduced detail and mild intestinal dilatation. Enrofloxacin (1.4 ml, Baytril® 2.5%), Metamizole (350 mg, Metapyrin®) and Dexamethason (1.8 mg) were administered through intravenous fluids. After no improvement in condition and poor prognosis, the animal was humanely euthanized for animal welfare reasons.

CONTACT Calvin Mehl  calvin.mehl@fli.de; Rainer G. Ulrich  rainer.ulrich@fli.de  Friedrich-Loeffler-Institut (FLI), Federal Research Institute for Animal Health, Institute of Novel and Emerging Infectious Diseases (INNT), Südufer 10, Greifswald-Insel Riems 17493, Germany
 Supplemental data for this article can be accessed online at <https://doi.org/10.1080/23144599.2023.2264084>

© 2023 The Author(s). Published by Informa UK Limited, trading as Taylor & Francis Group.

This is an Open Access article distributed under the terms of the Creative Commons Attribution-NonCommercial License (<http://creativecommons.org/licenses/by-nc/4.0/>), which permits unrestricted non-commercial use, distribution, and reproduction in any medium, provided the original work is properly cited. The terms on which this article has been published allow the posting of the Accepted Manuscript in a repository by the author(s) or with their consent.

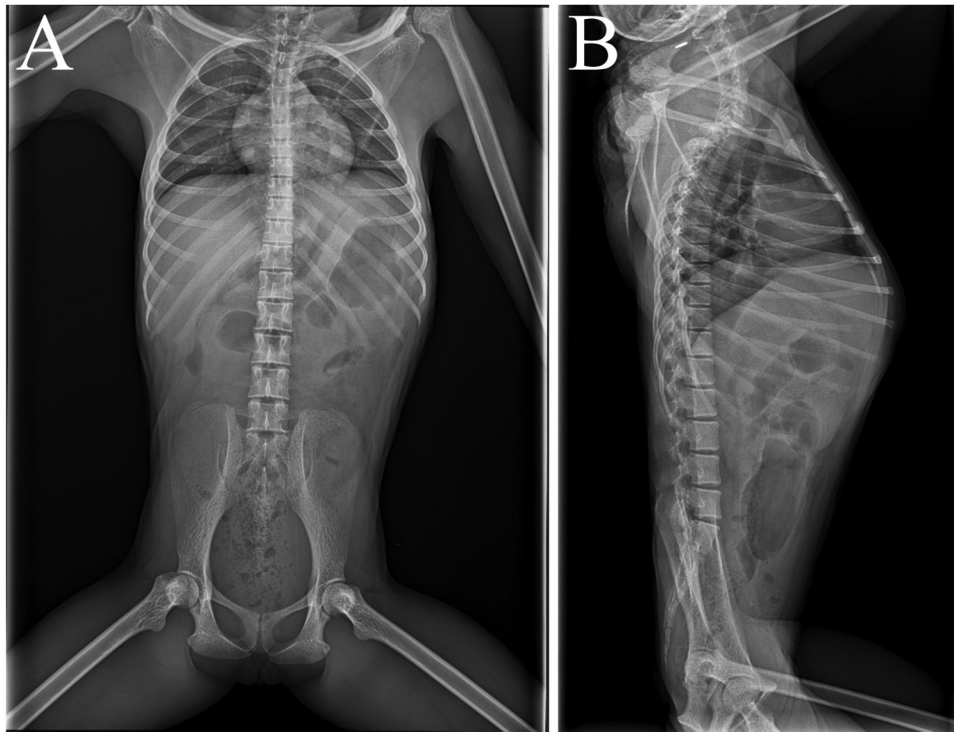


Figure 1. (A) ventrodorsal and (B) laterolateral x-rays of white-handed gibbon with *Francisella tularensis* subsp. *holarctica* infection show mild intestinal dilatation.

The gibbon cadaver was sent to the German Primate Center for necropsy. Necropsy revealed severe acute haemorrhagic enteritis in both the small and large intestines. Within the liver and spleen, a high-grade multifocal necrotizing hepatitis and splenitis could be demonstrated. Furthermore, erosive ulcerative lesions were present within the tongue followed by necrotizing inflammation within associated salivary gland and lymph node. The elevated necropsy and histologic findings were typical for tularaemia. Immunohistochemistry using a specific monoclonal anti-*F. tularensis* antibody confirmed the widespread distribution of *Francisella* antigen within the typical lesions in liver and spleen.

Important differential diagnostic diseases like toxoplasmosis or herpes simplex virus infection were excluded by immunohistochemistry, listeriosis and salmonellosis by bacteriologic investigation and echinococcosis by histology. Furthermore, special stains like Gram's, Giemsa, PAS-reaction, Grocott, and

Ziehl-Neelsen failed to demonstrate other microorganisms in any of the affected organs. A mild perivascular lymphocytic encephalitis and focal necrotizing pneumonia were important secondary findings indicating severe systemic infection.

Due to the typical pathologic findings an oropharyngeal and enteral form of tularaemia was diagnosed. Taking the incubation period of up to 14 days into consideration, the infection with the agent could have happened in both facilities.

To identify the source of the infection, pest rodents were collected from both zoos between late 2020 and early 2022 as part of routine pest management (using snap traps). These, as well as captive squirrels, were frozen at -20°C until dissection (FLI Riems) (Table 1) followed by the PCR screening of spleen tissue (FLI Jena). A single rat (*Rattus norvegicus*) from the receiving zoo was positive for *F. tularensis* by PCR, but sequencing of the PCR product and isolation were not possible.

Table 1. Rodents screened for *Francisella tularensis* DNA.

| Species | Number of positive animals/total number of animals |
|---|--|
| Sending zoo - Baden-Wuerttemberg | |
| Field mice (<i>Apodemus</i> sp.) | 0/2 |
| Bank vole (<i>Clethrionomys glareolus</i>) | 0/3 |
| House mouse (<i>Mus musculus</i>) | 0/101 |
| Norway rat (<i>Rattus norvegicus</i>) | 0/53 |
| Receiving zoo - Schleswig-Holstein | |
| Field mice (<i>Apodemus</i> sp.) | 0/5 |
| Common vole (<i>Microtus arvalis</i>) | 0/1 |
| Norway rat (<i>Rattus norvegicus</i>) | 1/85 |
| Swinhoe's striped squirrel (<i>Tamias swinhoei</i>) | 0/10 |

F. tularensis subsp. *holarctica* was isolated from the gibbon and identified as previously described [9]. Bacteria were isolated after being incubated at 37°C with 5% CO₂ for 72 hours. Following the manufacturer's instructions, DNA was extracted from the gibbon spleen tissue using the QIAGEN Genomic-tip 20/G and QIAGEN Genomic DNA buffer. Sequencing was then performed as previously described [9]. The genome sequence of 21T0109 (isolated from the gibbon) was compared to 306 previously sequenced German strains [9]. Raw sequencing data were all analyzed using the WGSBAC pipeline version 2.2.0 [9]. The raw read quality was controlled using FastQC version 0.11.7 [10]. Reads were assembled using Shovill v. 1.0.4 [11] and assessed using QUAST v. 5.0.2 [12]. Contamination was checked with Kraken2 v2.1.1 [13]. CanSNPer [14] and CanSNPer2 [15] were used for genotyping based on pre-defined canonical single nucleotide polymorphisms (SNPs). Additionally, Snippy 4.3.6 [16], which also created a core-genome (cg) alignment of all strains, was used to perform mapping-based SNP typing using OSU18 as a reference. Based on the alignment of the core genome, Snps-dists version 0.63 [17] estimated the pairwise SNP distances between the strains. Using Randomized Axelerated Maximum Likelihood (RAxML) version 8 [18], a phylogenetic tree based on the core-genome alignment was created using the

generalized time reversible model (GTR) with a gamma distribution and visualized using the interactive Tree of Life (iTOL) version 4 web application [19]. Five hundred repetitions of bootstrapping were performed and values larger 20 were visualized.

The *F. tularensis* whole genome sequence (21T0109, labelled in red) obtained from the gibbon-derived isolate clustered in major clade B.6, CanSnper1 subclade B.61, CanSnper2 further subdivided B.61 into subclade B.281 (Supplementary Figure S1). The most closely related sequence (16T0051, labelled in green) originated from the cadaver of a European brown hare (*Lepus europaeus*) in 2016, Stuttgart, Baden-Wuerttemberg (Figure 2). Of note, all other sequences within subclade B.281 originate from Baden-Wuerttemberg.

3. Discussion and conclusions

Although the *F. tularensis* infection in the white-handed gibbon could not be traced back to the source, several possible infection routes were identified. Firstly, the strain in the gibbon was most similar to an isolate from a hare in Stuttgart and fell within a subclade (B.281) solely represented by genome sequences obtained from hares from Baden-Wuerttemberg – the same federal state as the sending zoo. These sequences belonged to major clade B. 6 which can only rarely be

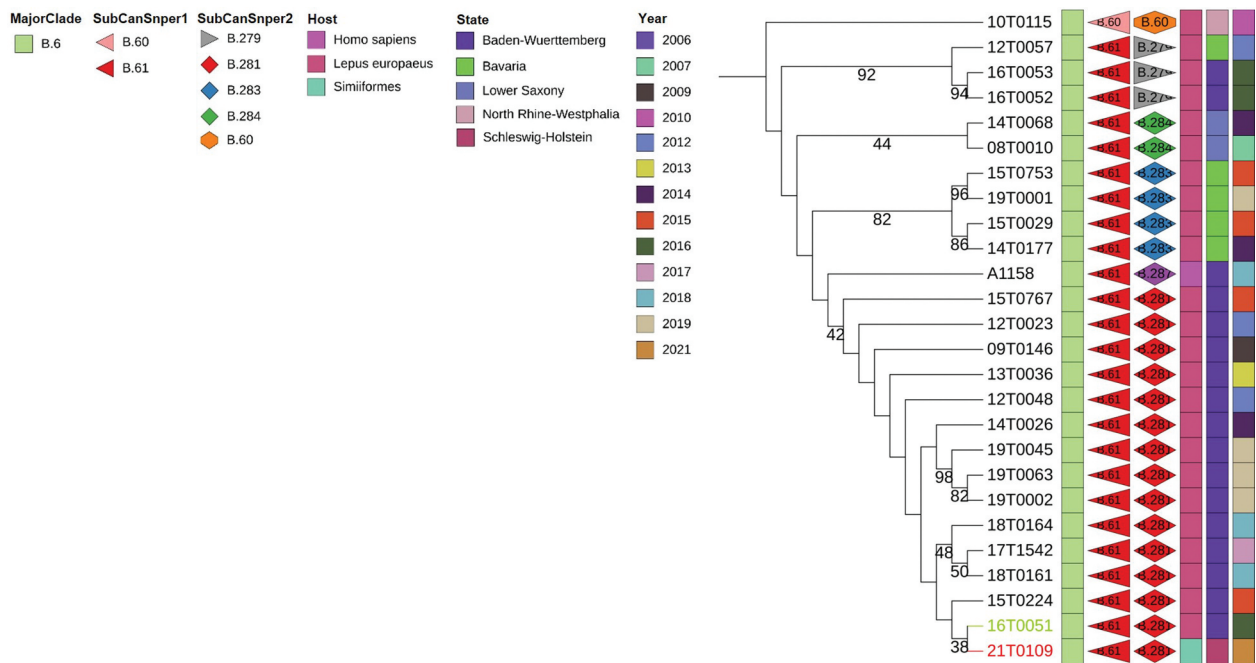


Figure 2. Subtree of the relevant clade of the phylogenetic tree of *Francisella tularensis* in Germany as shown in Supplementary Figure S1. This subtree is an enlarged section of the clade to which the gibbon sample clustered, indicated in the original tree by a black box. Symbols (colours and shapes) besides branches are explained in the corresponding columns of the legend (top left). Tree was calculated using published full genome sequences and visualized in iTOL. Reference strain OSU18 was used for rooting. Bootstrap values > 20 are given at the branches. Sequence from the white-handed gibbon (*Hylobates lar*) – derived isolate is shown in red (21T0109). Its closest relative in the data set, an isolate from a hare in Baden-Wuerttemberg (BW; 16T0051), is marked in green. As given in both panels in the left-hand upper corner: colours and shapes illustrate information for each sample (column 1 = major clade, column 2 = CanSnper1 subclade, column 3 = CanSnper2 subclade, column 4 = host species, column 5 = federal state, column 6 = year).

found in northern Germany [9]. However, because no comprehensive study on the distribution and sequence diversity exists for *F. tularensis* in Germany, it is possible that similar sequences can be found in other regions, namely the northern part of Germany where the receiving zoo is located. Secondly, at the receiving zoo in Schleswig-Holstein, a single rat was found PCR-positive for the bacterial DNA, however isolation of the bacterium was not possible. Additionally, symptoms typically present within 3–5 days of exposure [20], suggesting exposure may have occurred at the receiving zoo (the gibbon was asymptomatic at the time of transfer). However, depending on the dose, symptoms can also take up to 21 days to manifest [20]. Based on the necropsy results (bloody intestinal contents, accumulation of fluid in the abdomen, necrotizing splenitis and hepatitis) the exposure route was presumed to be oral [21,22] – potentially from contaminated water or food.

Similar to this study, the German Primate Center had an outbreak of *F. tularensis* in 2007 which showed similar pathology in infected cynomolgus monkeys (*Macaca fascicularis*) that were housed outdoors [22]. The authors described a similar clinical picture, including necrotizing hepatitis and splenitis, and suggest local wild rodents as the source of infections. Indeed, multiple small mammal species in Europe have been identified as potential sources of *F. tularensis* infection [4]. Furthermore, multiple studies have shown the risk of *F. tularensis* infection in non-human primates housed outdoors, almost all presenting with similar symptoms and many of which implicated rodents in the transmission of the pathogen [6,20,21]. In this study, there is evidence for the possible source of infection from both the sending and receiving zoos and more intensive screening and whole genome sequencing of *F. tularensis* isolates are necessary to confirm the source. Although the site at which the pathogen transmission occurred cannot be determined here, there is mounting evidence for the risk of *F. tularensis* infection from wild rodents, highlighting the need for pest rodent management in zoos.

Disclosure statement

No potential conflict of interest was reported by the authors.

Funding

This work was funded by DZIF Thematic Translational Unit (TTU) “Emerging Infections” (grant no. 01.808; awarded to R.G.U.).

ORCID

Calvin Mehl  <http://orcid.org/0000-0002-1885-7673>

Jörg Linde  <http://orcid.org/0000-0003-2727-9518>

Rainer G. Ulrich  <http://orcid.org/0000-0002-5620-1528>

Herbert Tomaso  <http://orcid.org/0000-0001-6657-833X>

Data availability statement

All data are given within the manuscript and its Supplementary material.

Ethical approval statement

The samples were collected during necropsy of an animal humanely euthanized according to animal welfare reasons. The animal was euthanized because of poor prognosis to avoid further pain and distress.

Ethical review and approval were not required for the animal study because all data used for this study were collected during clinical treatment and pathological examination and were obtained to diagnose the clinical case. All animal work followed relevant national and international guidelines. Good veterinary practice was followed in all procedures whenever animals were handled. Evaluation of data took place retrospectively. Written informed consent was obtained from the zoo owners for the participation of their animals in this study.

References

- [1] Müller W, Hotzel H, Otto P, et al. German *Francisella tularensis* isolates from European brown hares (*Lepus europaeus*) reveal genetic and phenotypic diversity. *BMC Microbiol.* 2013;13(1):1–9. doi: [10.1186/1471-2180-13-61](https://doi.org/10.1186/1471-2180-13-61)
- [2] Hennebique A, Boisset S, Maurin M. Tularaemia as a waterborne disease: a review. *Emerg Microbes Infect.* 2019;8(1):1027–1042. doi: [10.1080/22221751.2019.1638734](https://doi.org/10.1080/22221751.2019.1638734)
- [3] Taylor JP, Istre GR, McChesney TC, et al. Epidemiologic characteristics of human tularaemia in the southwest-central states, 1981–1987. *Am J Epidemiol.* 1991;133(10):1032–1038. doi: [10.1093/oxfordjournals.aje.a115812](https://doi.org/10.1093/oxfordjournals.aje.a115812)
- [4] Kaysser P, Seibold E, Mätz-Rensing K, et al. Re-emergence of tularaemia in Germany: presence of *Francisella tularensis* in different rodent species in endemic areas. *BMC Infect Dis.* 2008 Nov 17;8(1):157. doi: [10.1186/1471-2334-8-157](https://doi.org/10.1186/1471-2334-8-157)
- [5] Jeske K, Tomaso H, Imholt C, et al. Detection of *Francisella tularensis* in three vole species in Central Europe. *Transbound Emerg Dis.* 2019 Mar;66(2):1029–1032. doi: [10.1111/tbed.13078](https://doi.org/10.1111/tbed.13078)
- [6] Hofstetter I, Eckert J, Spletstoesser W, et al. Tularaemia outbreak in hare hunters in the Darmstadt-Dieburg district, Germany. *Euro Surveill.* 2006;11(3):2878. doi: [10.2807/esw.11.03.02878-en](https://doi.org/10.2807/esw.11.03.02878-en)
- [7] Spletstoesser WD, Mätz-Rensing K, Seibold E, et al. Re-emergence of *Francisella tularensis* in Germany: fatal tularaemia in a colony of semi-free-living marmosets (*Callithrix jacchus*). *Epidemiol Infect.* 2007 Nov;135(8):1256–1265. doi: [10.1017/S0950268807008035](https://doi.org/10.1017/S0950268807008035)

- [8] Appelt S, Faber M, Koppen K, et al. *Francisella tularensis* subspecies *holarctica* and tularaemia in Germany. *Microorganisms*. 2020 Sep 22;8(9):1448. doi: [10.3390/microorganisms8091448](https://doi.org/10.3390/microorganisms8091448)
- [9] Linde J, Homeier-Bachmann T, Dangel A, et al. Genotyping of *Francisella tularensis* subsp. *holarctica* from hares in Germany. *Microorganisms*. 2020 Dec 5;8(12):1932. doi: [10.3390/microorganisms8121932](https://doi.org/10.3390/microorganisms8121932)
- [10] Andrews S. FastQC: a quality control tool for high throughput sequence data. v. 0.11.5 ed. <https://www.bioinformatics.babraham.ac.uk/projects/fastqc/2018>.
- [11] Seemann T. Shovill GitHub. Assemble bacterial isolate genomes from Illumina paired-end reads. <https://github.com/tseemann/shovill2018>.
- [12] Gurevich A, Saveliev V, Vyahhi N, et al. QUAST: quality assessment tool for genome assemblies. *Bioinformatics*. 2013;29(8):1072–1075. doi: [10.1093/bioinformatics/btt086](https://doi.org/10.1093/bioinformatics/btt086)
- [13] Wood DE, Lu J, Langmead B. Improved metagenomic analysis with Kraken 2. *Genome Biol*. 2019;20(1):257. doi: [10.1186/s13059-019-1891-0](https://doi.org/10.1186/s13059-019-1891-0)
- [14] Larkeryd A, Myrtennas K, Karlsson E, et al. CanSNPer: a hierarchical genotype classifier of clonal pathogens. *Bioinformatics*. 2014;30(12):1762–1764. doi: [10.1093/bioinformatics/btu113](https://doi.org/10.1093/bioinformatics/btu113)
- [15] FOI-Bioinformatics. CanSNPer2: a toolkit for SNP-typing NGS data. 2020. <https://github.com/FOI-Bioinformatics/CanSNPer2>.
- [16] Seemann T. Snippy GitHub. <https://github.com/tseemann/snippy2014>.
- [17] Seemann T. snp-dists 2018. <https://github.com/tseemann/snp-dists>.
- [18] Stamatakis A. RAxML version 8: a tool for phylogenetic analysis and post-analysis of large phylogenies. *Bioinformatics*. 2014;30(9):1312–1313. doi: [10.1093/bioinformatics/btu033](https://doi.org/10.1093/bioinformatics/btu033)
- [19] Letunic I, Bork P. Interactive tree of life (iTOL) v4: recent updates and new developments. *Nucleic Acids Res*. 2019;47(W1):W256–W9. doi: [10.1093/nar/gkz239](https://doi.org/10.1093/nar/gkz239)
- [20] Tarnvik A, Berglund L. Tularaemia. *Eur Respir J*. 2003 Feb;21(2):361–373. doi: [10.1183/09031936.03.00088903](https://doi.org/10.1183/09031936.03.00088903)
- [21] KuoLee R, Zhao X, Austin J, et al. Mouse model of oral infection with virulent type a *Francisella tularensis*. *Infect Immun*. 2007 Apr;75(4):1651–1660. doi: [10.1128/IAI.01834-06](https://doi.org/10.1128/IAI.01834-06)
- [22] Mätz-Rensing K, Floto A, Schrod A, et al. Epizootic of tularaemia in an outdoor housed group of cynomolgus monkeys (*Macaca fascicularis*). *Vet Pathol*. 2007;44(3):327–334. doi: [10.1354/vp.44-3-327](https://doi.org/10.1354/vp.44-3-327)